

PALPATION OF THE TESTES IN DRAFTEES: ACCEPTANCE ON THE OCCASION OF MUSTER AND IMPLICATION FOR HEALTH PROMOTION

HERMANN C. ROEMER^{1,2}, MARTIN VON KATHEN¹, WOLFGANG SCHÖPS³, and KLAUS GOLKA²

¹ Military Medical Center

Düsseldorf, Germany

² Institute for Occupational Physiology

University of Dortmund

Dortmund, Germany

³ Department of Urology

District Hospital

Mechernich, Germany

Abstract

Objectives: Testicular cancer is the most prevalent malignant neoplasm in young men. The key problem in screening for malignant testicular tumors and their main risk factors (undescended testes and testes which descended only after medical treatment) is to reach the target group of “young men”. **Materials and Methods:** In five different military medical centers of German Armed Forces, 1600 young draftees were investigated by a standardized interview at recruitment examination between 2001 and 2003. **Results:** Ninety-five percent of respondents reported that they had been palpated at testes during physical examination. The percentage of draftees not palpated at their testes varied between muster centers, but did not depend on the physician’s gender. Only two draftees had refused explicitly the palpation of testes. The prevalence of observed pathologic alterations of the testes was 1.69%, including two cases of cryptorchidism, 19 of varicocele, and 6 cases with other benign alterations. **Conclusions:** The simple and effective examination of testes should not be restricted to draftees, but promoted by compulsory health insurance funds, offered and performed routinely by all physicians who have access to the target group of “young men”.

Key words:

Testicles, Screening, Physical examination, Muster, Health promotion

INTRODUCTION

Testicular cancer is the most prevalent malignant neoplasm in young men [1]. In Germany, about 2500 young men are affected by malignant testicular tumors every year [2], which means 20–30% of all men who develop malignant tumors before the age of 40. The highest worldwide incidence of testicular cancer has been observed in Denmark [3]. The lowest disease rates are found in Finland, Spain, Portugal and Luxembourg [4].

There is a growing incidence of testicular cancer worldwide. Over the previous decades, however, its etiology has remained still unclear. Well known risk factors are: contralateral malignant testicular tumor [5], cryptorchidism [6], testicles which descended only due to therapy [7] and the inherited diseases like Down’s syndrome and Carney complex [8,9] as well as maternal treatment with diethylstilbestrol as tocolytic [10].

Received: August 30, 2006. Accepted: October 10, 2006.

Address reprint requests to Prof. K. Golka, MD, Institute for Occupational Physiology at the University of Dortmund, Ardeystrasse 67, D-44139 Dortmund, Germany (e-mail: golka@arb-phys.uni-dortmund.de).

Different possible risk factors for malignant testicular tumors have been described, such as genetic predisposition (blood relationship of the first degree), hormonally active substances (estrogens in drinking water), prenatal factors (low birth weight), chemicals (endocrine disruptors) as well as exposures to emissions of combustion engines, oils and gases at workplace and in the environment [11–14].

An early diagnosis of malignant testicular tumors increases the cure rate up to 95%. It also simplifies significantly the medical treatment and can clearly reduce therapeutic stress in the patients. A diagnostic delay correlates with a diminished cure rate. A history of 14–20 weeks with testes complaints is common in Germany. In a large study carried out in the UK, the authors reported a patient-related delay, depending on the dissemination of the disease: 1 month for testicular cancer limited to testis, epididymis and chord, 1.25 months for a disease disseminated to retroperitoneal nodes only, and 2 months for metastatic disease above diaphragm or for extranodal abdominal involvement [15].

The key problem in screening for malignant testicular tumors and their main risk factors (undescended testes (syn: cryptorchidism), testes which descended only after medical treatment) is to reach the target group of “young men”.

In some countries like Germany, the only available screening for testicular tumors is the palpation of the testes on the occasion of the physical examination at muster. Declining numbers of draftees (for physical examination) have diminished the opportunities for an early diagnosis of malignant testicular tumors in young men, thus demonstrating the fundamental role of inspection and palpation of testes within the range of physical examinations. Unfortunately, this situation will become even worse with time. On the occasion of muster, also different benign alterations of the testes are observed, for instance varicoceles and hydroceles.

The most frequently observed benign pathologic alteration of the testes in young men is varicocele. Due to side-related differences of the spermatic veins in entering the renal vein and the caval vein, respectively, varicoceles of the left testis appear much more frequently. The preva-

lence of varicoceles greatly depends on the examination method applied and the grades of varicoceles included. In young men, the prevalence varying between 11 and 34% has been reported [16]. Varicoceles palpable in a patient lying on his back are suspected to be symptomatic ones and thus must be further investigated by ultrasound or other imaging techniques. In some studies, an improved seminal fluid and/or increased testicular volume have been observed after varicocelectomy [17,18]. The prevalence of other benign alterations in testes is much lower. Unfortunately, data on the prevalence of other benign alterations of the testes in the general population of young men are not available.

In hospitals as well as in doctors' multidisciplinary practices, routine palpation of the testes is postulated for the diagnosis and sufficient therapy of malignant testicular tumors [19]. An early diagnosis of testicular cancer and its predisposing factors is a challenge for all physicians, but it may be of a particular relevance to physicians working in the field of preventive medicine. Specialists in occupational medicine, general medicine and sports medicine have good access to the target group of “young men”. Thus they can take up in cooperation with compulsory health insurance funds, the area of prevention and early diagnosis of testicular cancer and integrate it into existing schemes of routine medical examinations at work.

MATERIALS AND METHODS

Between 2001 and 2003, 1600 young draftees who had undergone physical examination on the occasion of their mustering into the army in 71 centers across Germany were investigated in five different military medical centers of German Armed Forces. A standardized interview was conducted at the office recruitment examination (i.e., on the first working day in the Armed Forces) to collect the following data: date of birth, year of muster, palpation of the testes performed, gender of the examining physician, testicular complaints reported before the examination, pathologic findings and, if applicable, the revealed diagnosis. All physicians who examined the draftees at muster were obliged to record and code all pathological findings

(i.e., deviations from normal findings) and to refer all patients with pathological symptoms to a urologist for further examinations. The examination to the office was on average performed 2 years after muster. None of the draftees refused to participate in the interview. Young men who were exempted from military service as a result of a disease (including testicular cancer and high-grade forms of varicoceles) were not eligible for the study.

RESULTS

Of the 1600 young men examined, 95.4% reported palpation of the testes. The percentage of draftees not being palpated at the testes varied from 0 to 8.3% between 9 major muster centers where 1375 of 1600 draftees had been examined. The physician's gender revealed no significant impact. Two draftees had refused explicitly the palpation of the testes during physical examinations. Furthermore, as many as 27 cases of benign findings of testes were diagnosed, including cases of cryptorchidism, 19 of varicocele and 6 of other benign alterations (Fig. 1), which means the prevalence of pathologic alterations in 1.69% of the study population.

DISCUSSION

Testicular cancer is the most common malignancy in men in the 20–30 age group and the second most common malignancy in the 15–19 and 31–39 age groups. This tumor can be easily identified by screening methods based on

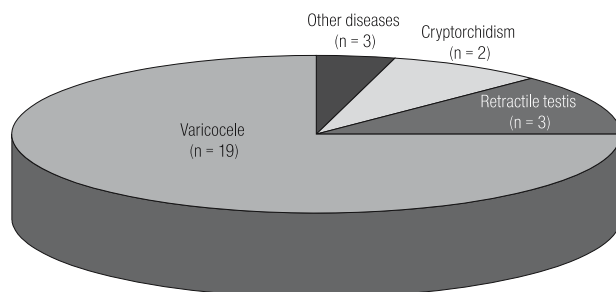


Fig. 1. Benign findings of testes alterations ($n = 27$) observed on the occasion of physical examinations at muster in 1600 reviewed draftees. (Other diseases: status after torsion of the testis, status after inflammation of the testis, remarkable difference in size compared to the contralateral testis).

palpation due to its cardinal symptoms, i.e., painless swelling of the testis or a nodule at an early stage. In about 10% of the cases, metastases may be manifested by cough or dyspnea (pulmonary metastases) or lumbar back pain (bulky retroperitoneal metastases) [20]. Other testicular malignancy related symptoms are given in Table 1.

Unfortunately, men rarely participate in cancer screening examinations provided by the compulsory health insurance funds. Possible offer of palpation of testes in adolescent males, comparable to screening of women provided by the compulsory health insurance funds, may contribute to increasing health awareness among men. Senior scientists urgently recommend screening and early diagnosis of malignant testicular tumor in young men [2,6].

Screening methods for malignant testicular tumors in young men should be offered as early as possible. The time of testes dislocation into the scrotum correlates with a limited reduction of risk to develop testicular cancer [7]. Awareness of the risk and the importance of regular checking the testes by themselves or by a physician should

Table 1. Symptoms of testicular malignancy

Symptom	Site of metastases
Early and advanced disease	
Painless swelling of one testis	(?)
Nodule at one testis	(?)
Hardness of one testis	(?)
Feeling of "increasing weight of the testis"	(?)
Feeling of "tension" in the testis (due to rapid tumor growth)	(?)
Advanced disease	
Cough, dyspnea	Lung
Lumbar back pain	Retroperitoneum
Bone pain	Skeleton
Central nervous symptoms	Brain
Peripheral nervous symptoms	Spinal cord, local tumor mass
Lower extremity swelling	Close to iliac or caval vein (or thrombosis!)
Gynecomastia	Hormonally active tumor (metastases not necessarily)
Other hormone-related symptoms	Hormonally active tumor (metastases not necessarily)

be enhanced in this age group, especially in young men treated for cryptorchidism.

The interview conducted on the occasion of physical examination at muster shows that even at this age untreated cryptorchidism, a documented risk factor, can be diagnosed. Besides, some benign alterations of the testes, such as varicoceles, the most frequent pathological finding of the testes in young men, may be observed.

Over decades, the examination during muster has offered routine physical examination, including inspection and palpation of testes, to the risk group of young men. The actual number of testicular cancer cases observed on the occasion of muster is not known, but between 1983 and 1998, 0.19% of all examined draftees were subjected to further medical examinations to exclude testicular malignancies.

However, this unique possibility of prevention and early specific diagnosis of malignant testicular tumors does not include all men of the age risk groups. Due to the reshuffling of the German Armed Forces, the fraction of the examined 19-year-old men is steadily decreasing. The percentage of the examined 19-year-old draftees in Germany decreased from 75 in 1983 to 40 in 1998. Thus, in 1998, 60% of draftees in this age group were not subjected to routine examination, and the upward tendency can be expected in the future.

To reach an adequate number of young men, the development of a preventive program could be promising. Inspection and palpation of testes are simple and effective physical examination methods of detecting malignant testicular tumors in young men without adverse effects. They are also practical and easy to learn by every physician. The intention of screening for testicular cancer by palpation is to identify any testis affected by tumor at an early stage without invasive and/or costly examination methods. All suspected findings must be referred to a urologist who can make actual diagnosis due to his or her clinical experience and, if needed, apply ultrasound examination of the testis and/or check laboratory parameters (Table 2).

Another approach to detect testicular cancer is to promote self-examination of the testes in young men. It would

Table 2. Common differential diagnoses of the palpable testicular mass

Malignant testicular tumor
Secondary tumors of the testis (lymphoma!)
Chronic epididymitis
Hydrocele
Spermatocele
Varicocele
Late sequela of testicular trauma
Scrotal hernia

be very helpful if young men could palpate their testes routinely like many women do in regard to their breasts. The main advantage of self-examination is the chance to detect any change in the testis at its very early stage. Unfortunately, different attempts to increase the rate of early detected testicular malignomas by self-examination have failed [21]. The US study on adolescent boys organized in a community-based youth organization revealed that nearly 73% of the boys had heard about testicular cancer, but only 10.3% of them performed testicular self-examination according to current recommendations (10 or more times per year) [22]. The results of this study are in line with other studies carried out among ninth to twelfth graders, revealing that more than 80% of boys in this age group never performed a testicular self-examination and that less than 10% performed it once a month [22]. As stated above, a remarkable number of men do not consult a physician about early cancer detection programs. Therefore, the results in early detection of testicular cancer are really disappointing. This is in line with the UK finding that the median size of testicular tumors at the time of surgery has only decreased from 5.4 to 4.5 cm over the past 20 years [23].

Nevertheless, it must be born in mind that some testicular malignancies cannot be identified by palpation only. For example, rare burnt-out tumors of the testis (e.g., spontaneous complete or greater than 50% regression of the primary testicular cancer), which do not appear as tumor-bearing testis to the palpating physician, cannot be identified by palpation although they may have metastasized extensively. Furthermore, very small tumors may be overlooked by palpation only.

Unfortunately, particular examination of the testes is not a key element of physical examination worldwide. One more important factor might be the sense of shame experienced by both the patient and the physician. Interestingly, no gender effect on the participation in the physical examination of the testes could be observed in the presented study.

The palpation of testes by a urologist is in fact the indisputable clinical examination method by choice ("gold standard"). However, in view of the fact that young men hardly ever visit the urologist for early diagnosis of malignant testicular tumors, it cannot be expected that offering screening examination under the compulsory health insurance would change this situation. Hence, the most promising way is an accurate and routine palpation of testes by a non-urologist and referring pathologic findings to a urologist for the clarification of the case. At very early tumor stages excising of tumor-bearing testicle and close follow-up provide an alternative to cytostatic agents and radiotherapy. Thereby the intensely impairing and costly chemotherapy or radiotherapy can be replaced by a less aggressive therapy, which can even spare a considerable fraction of young men. From the medical and economical point of view, this procedure offers a considerable benefit.

It is recommended to offer the identification of risk factors for testicular cancer and their reduction (primary prevention) and to motivate and instruct young men about regular self-examination of testes and early diagnosis of testicular cancer (secondary prevention) on the occasion of examinations, which young men frequently have to undergo.

CONCLUSIONS

With the help of the compulsory health insurance funds, physicians particularly those specialized in occupational medicine, sports medicine and general medicine can assist in establishing an efficient, cost-saving and nationwide screening program for the prevention and early detection of testicular cancer targeted at young men who form a potential risk group.

ACKNOWLEDGEMENT

The authors would like to thank Werner Lüdde, Institut für Wehrmedizinostatistik und Berichtswesen, Remagen for excellent technical support.

REFERENCES

1. Pottern LM, Brown LM, Devesa SS. *Epidemiology and pathogenetics of testicular cancer*. In: Ernstoff MS, Heaney JA, Peschel RE, editors. *Testicular and Penile Cancer*. Boston: Blackwell Science; 1999. pp. 2–10.
2. Rübber H. *Anonymous: Inzidenz von Hodenkrebs hat stark zugenommen*. *Ärztezeitung*; 1999 Sept 24. Available from: <http://www.aerztezeitung.de/de/htm/net/krebs/172a1501.htm>.
3. Möller H, Prener A, Skakkebaek NE. *Testicular cancer, cryptorchidism, inguinal hernia, testicular atrophy, and genital malformations: case-control studies in Denmark*. *Cancer Causes Control* 1996;7:264–74.
4. Bergström R, Adami HO, Möhner M, Zatonski W, Storm H, Ekblom A, et al. *Increase in testicular cancer incidence in six European countries. A birth cohort phenomenon*. *J Natl Cancer Inst* 1996;88:727–33.
5. van Leeuwen FE, Stiggelbout AM, van den Belt-Dusebout AW, Noyon R, Elie MR, van Kerkhoff EH, et al. *Second cancer risk following testicular cancer: A follow-up study of 1909 patients*. *J Clin Oncol* 1993;11:415–24.
6. Kinkade S. *Testicular cancer*. *Am Fam Physician* 1999;59:2539–44,2549–50.
7. Anonymous. *Aetiology of testicular cancer: association with congenital abnormalities, age at puberty, infertility, and exercise*. *United Kingdom Testicular Cancer Study Group*. *BMJ* 1994;308:1393–9.
8. Yang Q, Rasmussen SA, Friedmann JM. *Mortality associated with Down's syndrome in the USA from 1983 to 1997: A population-based study*. *Lancet* 2002;359:1019–25.
9. Adler G, Burg G, Kunze J, Pongratz D, Schinzel A, Spranger J. *Leiber – Die klinischen Syndrome. Syndrome, Sequenzen und Symptomenkomplexe*. 8th ed, München: Urban & Schwarzenberg; 1996.
10. Marselos M, Tomatis L. *Diethylstilboestrol. I. Pharmacology, toxicology and carcinogenicity in humans*. *Eur J Cancer* 1992;28A:1182–9.
11. Westergaard T, Olsen JH, Frisch M, Kronman N, Neilsen JW, Melbye M. *Cancer risk in fathers and brothers of testicular cancer patients in Denmark: a population-based study*. *Int J Cancer* 1996;66:627–31.
12. McLachlan JA, Newbold RR, Li S, Negishi M. *Are estrogens carcinogenic during development of the testes?* *APMIS* 1998;106:240–2.

13. Skakkebaek NE, Rajpert-De Meyts E, Jorgensen N, Carlsen E, Petersen PM, Giwerman A, et al. *Germ cell cancer and disorders of spermatogenesis: an environmental connection?* APMIS 1998;106:3–11.
14. Garland FC, Gorham ED, Garland CF, Ducatman AM. *Testicular cancer in US Navy personnel.* Am J Epidemiol 1988;127:411–4.
15. Bosl GJ, Vogelzang NJ, Goldman A, Fraley EE, Lange PH, Levitt SH, et al. *Impact of delay in diagnosis on clinical stage of testicular cancer.* Lancet 1981;2(8253):970–3.
16. Pfeiffer D, Berger J, Schoop C, Tauber R. *A Doppler-based study on the prevalence of varicocele in German children and adolescents.* Andrologia 2006;38:13–9.
17. Isidori AM, Pozza C, Gianfrilli D, Isidori A. *Medical treatment to improve sperm quality.* Reprod Biomed Online 2006;12:704–14.
18. Zucchi A, Mearini L, Mearini E, Fioretti F, Bini V, Porena M. *Varicocele and fertility: relationship between testicular volume and seminal parameters before and after treatment.* J Androl 2006;27:548–51.
19. Schmoll HJ, Weissbach L, Bamberg M. *Therapie des Hodentumors: das Zauberwort heißt Interdisziplinarität.* Onkologe 1998;4:471–2.
20. Richie JP, Steele GS. *Neoplasms of the testis.* In: Walsh PC, Retik AB, Vaughan ED, Wein AJ, editors. *Campbell's Urology.* Vol. 4. 8th ed. Philadelphia (PA): Saunders; 2002. pp. 2876–944.
21. Sheley JF, Kinchen EW, Morgan DH, Gordon DF. *Limited impact of testicular self-examination promotion.* J Commun Health 1991;16:117–24.
22. Ward KD, Vander Weg MW, Read MC, Sell MA, Beech BM. *Testicular cancer awareness and self-examination among adolescent males in a community-based youth organization.* Prev Med 2005;41:386–98.
23. Oliver RT. *Trends in testicular cancer.* Lancet 2001;358:841.